

MESOTHELIOMA AND SUICIDE

Dr.İzzettin BARIŞ

Medical History

He wrote a letter before stabbing himself. "I have severe chest pain. My lungs are destroyed. Can't oxygenise my blood. I have fever. I can't sleep or eat. I lost 7 kgs. I have visited many times in the ER of university hospital. Physician diagnosed asbestos pleural calcification. They said this is not a disease doesn't cause chest pain. I was diagnosed as psychiatric illness. I kept my medical file in order to show other doctor. They sent a police man to get back file and sue me. I decided not to live with this pain. No body responsible for this." I stabbed my both hemithorax and abdomen 13 times in the bathroom.

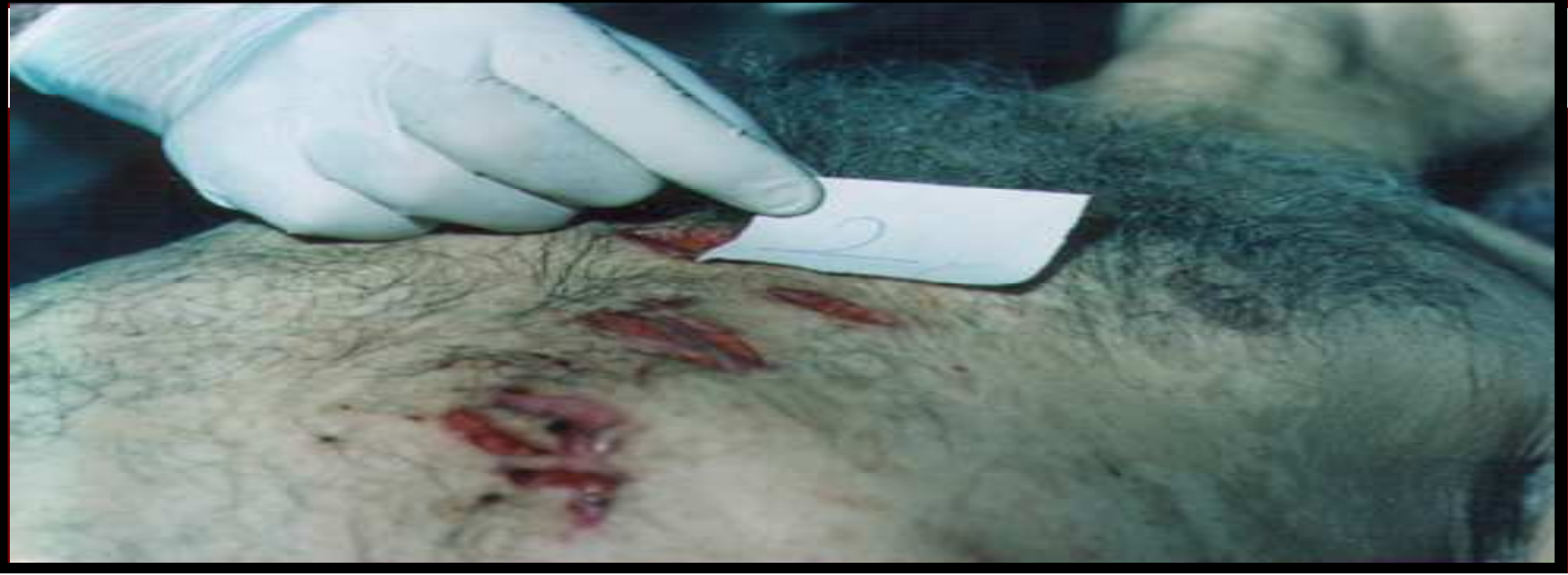Coronary autopsy had been done. Pathological exam. Reported as proliferative mesothelial cells. Chronic fibrosing pleuritis due to environmental asbestos exposure.

Dr. Y.İ. Barış's diagnosis environmental asbestos related calcified pleural plaques and malignant mesothelioma

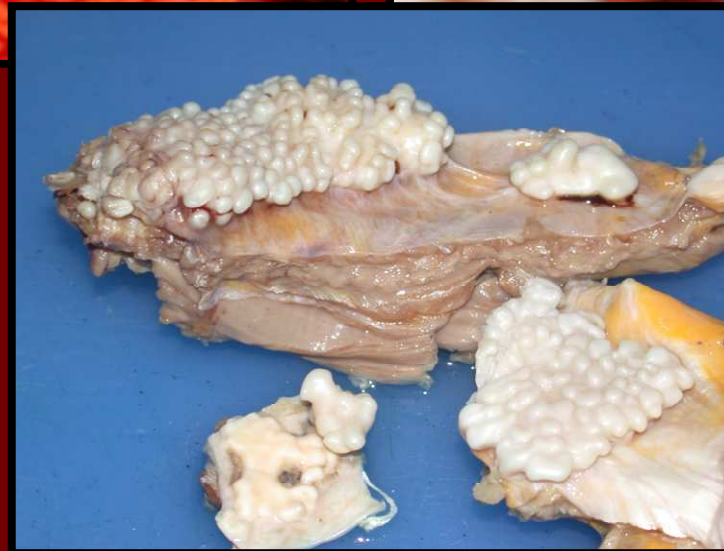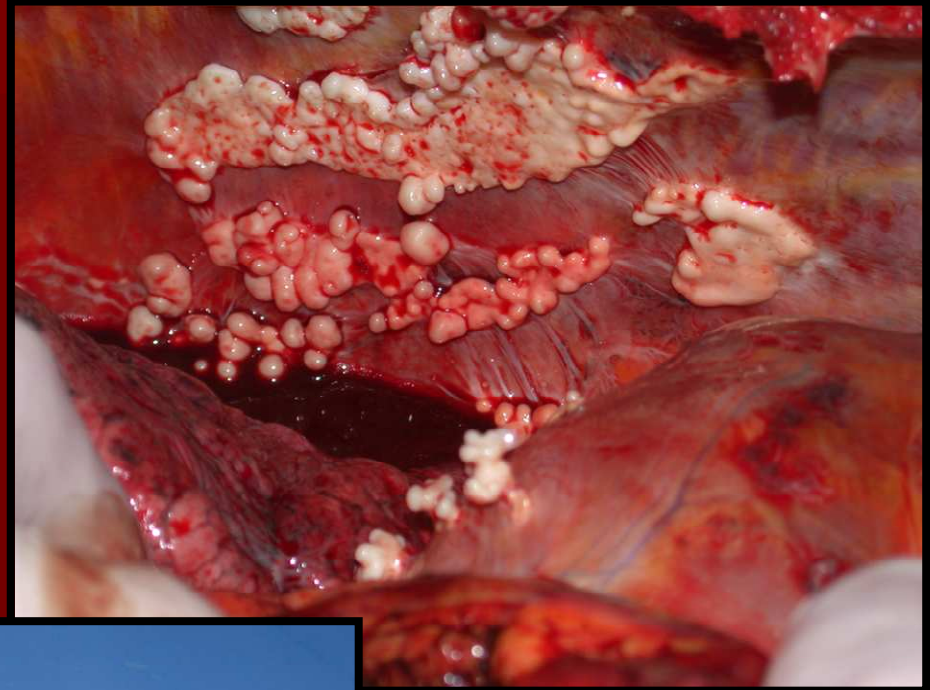
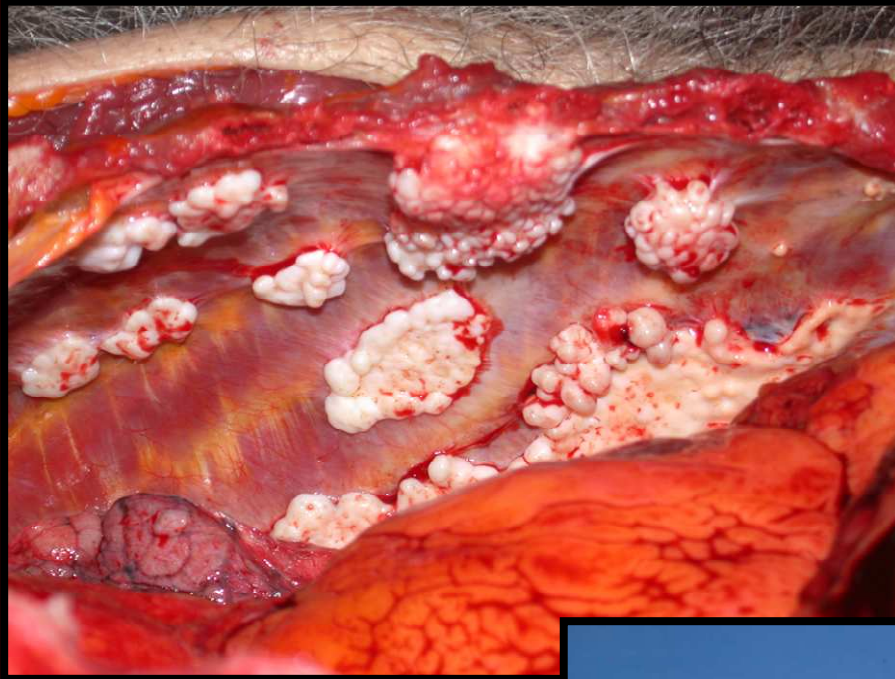


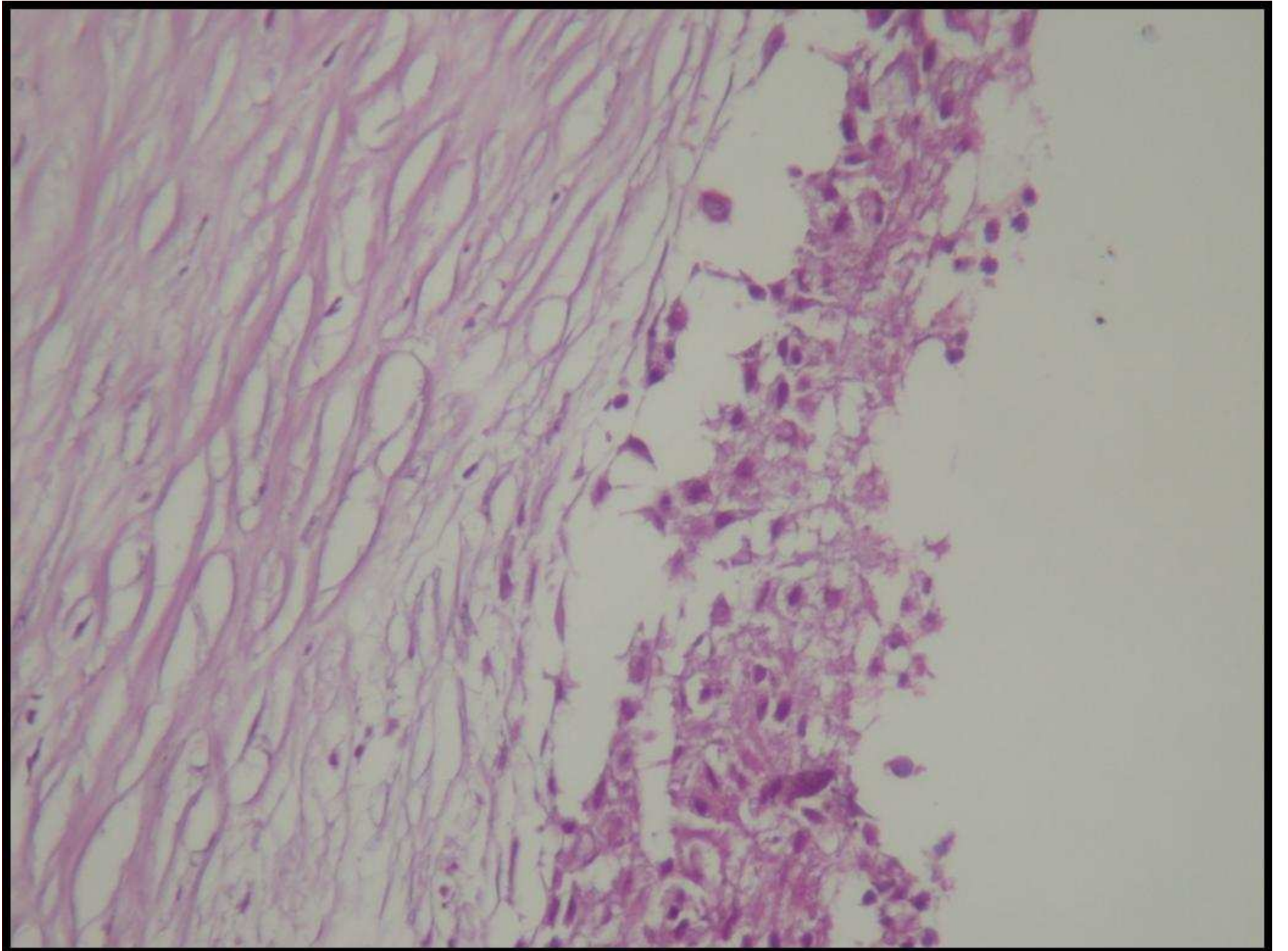
5 56 56

nisin daha ⁴ başka sekile
 girdiyini anlatıyor ve için-
 için pece pürdüz uyu-
 muyor her dokunuyorlarken. Dis-
 şünlükçe Atsciperlerini dikandiyini
 kaanın temizlenmediğini vücudunda
 oksijen olmadığını oksijen olmadığı için
 uyuyamadığını anlatmaya başlıyor.



Autopsy Pictures







Koparan villager collecting asbestos mixed white soil



White stucco on the wall of a house from south-eastern Turkey

20µm

